NAME ______________________ LAB TIME/DATE ______________________

REVIEW SHEET

The Language of Anatomy

Surface Anatomy

1. Match each of the following descriptions with a key equivalent, and record the key letter or term in front of the description.

Key: a. buccal b. calcaneal c. deltoid d. digital e. patellar f. scapular

a 1. cheek

d 2. pertaining to the fingers

f 3. shoulder blade region

e 4. anterior aspect of knee

b 5. heel of foot

c 6. curve of shoulder

2. Indicate the following body areas on the accompanying diagram by placing the correct key letter at the end of each line.

Key:

a. abdominal
b. antecubital
c. axillary
d. brachial
e. cervical
f. femoral
g. gluteal
h. inguinal
i. lumbar
j. occipital
k. oral
l. popliteal
m. pubic
n. sural
o. thoracic
p. umbilical

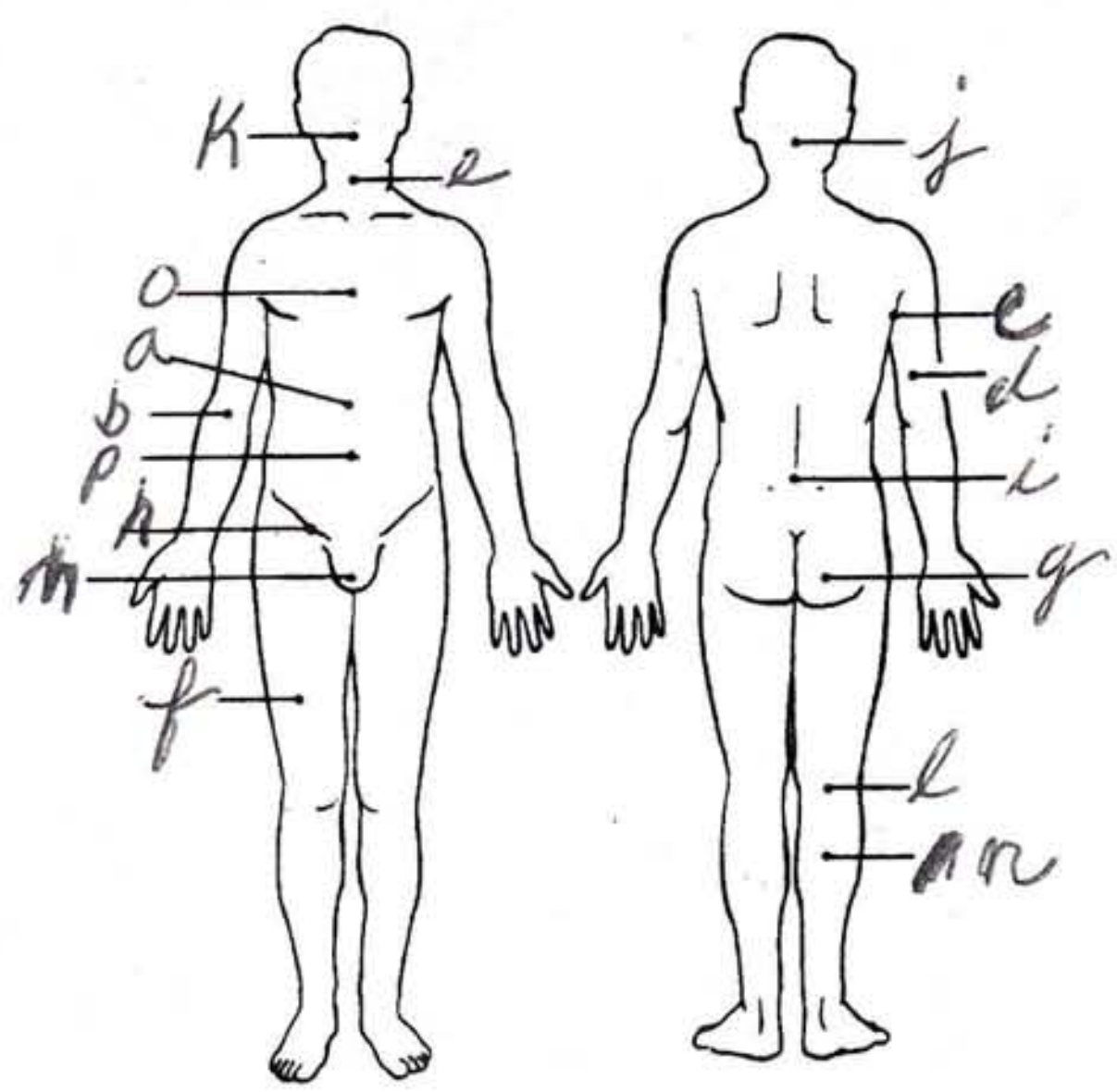

3. Classify each of the surface anatomy terms in the key of question 2 above, into one of the body regions indicated below. Insert the appropriate key letters on the answer blanks.

~~m, h~~ b, f, c, d, l, n 1. Appendicular

k, e, o, a, p, m, j, i, g, h 2. Axial

Body Orientation, Direction, Planes, and Sections

1. Describe completely the standard human anatomical position. Standing erect, feet together head and toes pointed forward, arms hanging on side ~~fo~~ with palms forward

2. Define *section:* A cut made along a body plane

3. Several incomplete statements are listed below. Correctly complete each statement by choosing the appropriate anatomical term from the key. Record the key letters and/or terms on the correspondingly numbered blanks below.

Key:		
a. anterior	e. lateral	i. sagittal
b. distal	f. medial	j. superior
c. frontal	g. posterior	k. transverse
d. inferior	h. proximal	

In the anatomical position, the face and palms are on the __1__ body surface; the buttocks and shoulder blades are on the __2__ body surface; and the top of the head is the most __3__ part of the body. The ears are __4__ and __4__ to the shoulders and __5__ to the nose. The heart is __6__ to the vertebral column (spine) and __7__ to the lungs. The elbow is __8__ to the fingers but __9__ to the shoulder. The abdominopelvic cavity is __10__ to the thoracic cavity and __11__ to the spinal cavity. In humans, the dorsal surface can also be called the __12__ surface; however, in quadruped animals, the dorsal surface is the __13__ surface.

If an incision cuts the heart into right and left parts, the section is a __14__ section; but if the heart is cut so that superior and inferior portions result, the section is a __15__ section. You are told to cut a dissection animal along two planes so that the kidneys are observable in both sections. The two sections that meet this requirement are the __16__ and __17__ sections.

1. a
2. g
3. j
4. f, j
5. e
6. a
7. f
8. h
9. b
10. d
11. a
12. g
13. j
14. i
15. K
16. C
17. K

4. Correctly identify each of the body planes by inserting the appropriate term for each on the answer line below the drawing.

1. media or mid sagittal
2. frontal or coronal
3. transverse

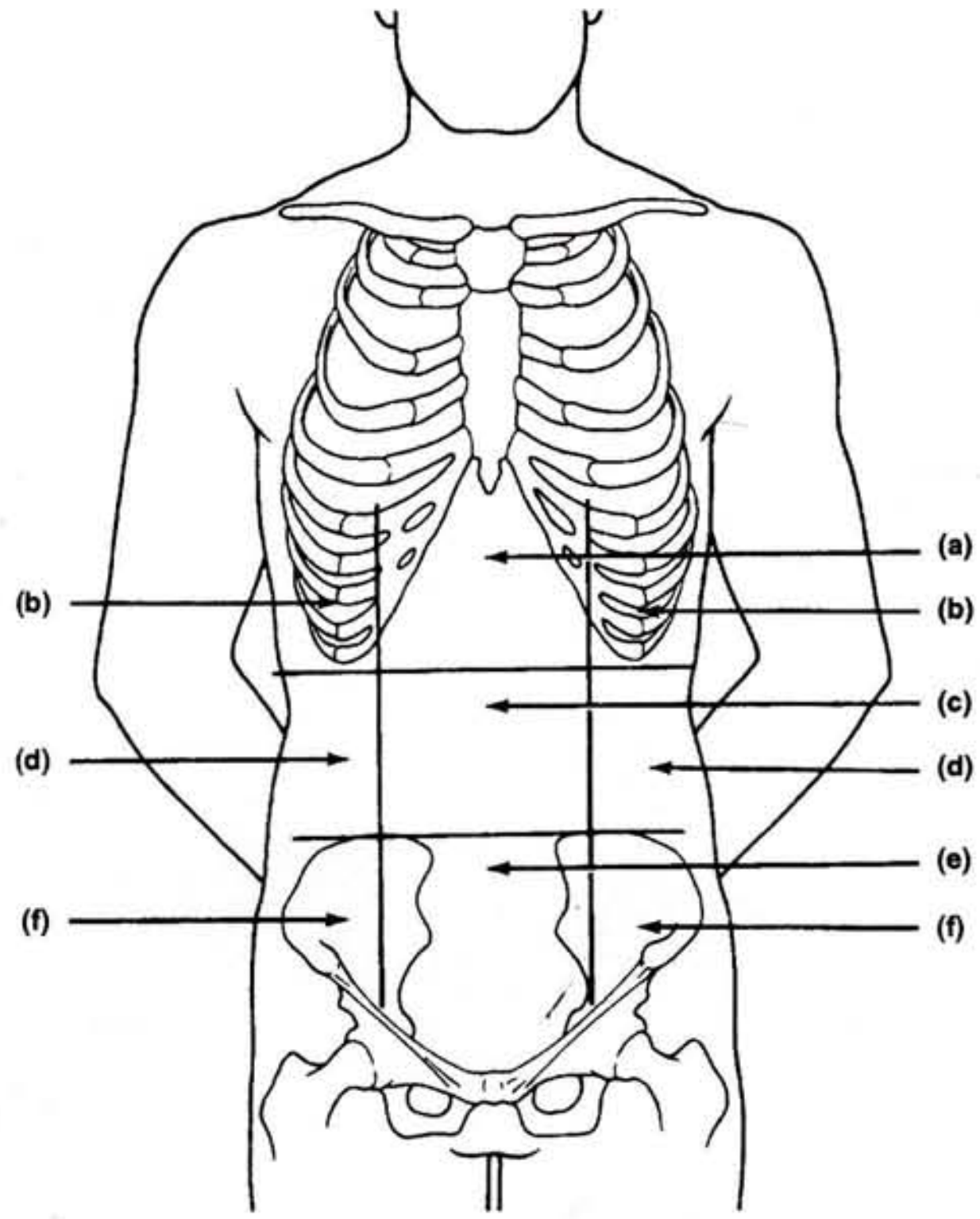

5. Correctly identify each of the nine areas of the abdominal surface by inserting the appropriate term for each of the letters indicated in the drawing just above.

a. eigastric region
right b. + left hypochondriac
c. umbilical region
rt+lf d. lumbar regions
e. hypogastric
f. right & left iliac regions

Body Cavities

1. Which body cavity would have to be opened for the following types of surgery? (Insert letter of key choice in same-numbered blank. More than one choice may apply.)

Key: a. abdominopelvic b. cranial c. dorsal d. spinal e. thoracic f. ventral

f/e 1. surgery to remove a cancerous lung lobe e
f 2. removal of the uterus or womb a
c 3. removal of a brain tumor b
f 4. appendectomy a
b/f 5. stomach ulcer operation a

The abdominopelvic and thoracic cavities are subdivisions of the f 6 body cavity, while the cranial and spinal cavities are subdivisions of the c 7 body cavity. The c 8 body cavity is totally surrounded by bone, and thus affords its contained structures very good protection.

2. Name the serous membranes covering the lungs (#1), the heart (#2), and the organs of the abdominopelvic cavity (#3), and insert your responses in the blanks on the right.

1. pleural
2. pericardial
3. peritonal

3. Name the muscle that subdivides the ventral body cavity. diaphragm

4. Which of the following organ systems are represented in all three subdivisions of the ventral body cavity? (Circle all appropriate responses.)

respiratory · circulatory · reproductive · lymphatic
nervous · excretory (urinary) · muscular · integumentary

5. Which organ system would not be represented in any of the body cavities? integumentary

6. What are the bony landmarks of the abdominopelvic cavity?
pelvic bones, vertebral colum and rib cage

7. Which body cavity affords the least protection to its internal structures? abdominal

8. What is the function of the serous membranes of the body?
protection - cushions with fluid
allows for smooth movement of organs

9. A nurse informs you that she is about to take blood from the antecubital region. What portion of your body should you present to her? arm - anterior side of elbow

10. What do peritonitis, pleurisy, and pericarditis (pathologic conditions) have in common?
An infection of the serous membranes resulting in limited fluid serous protection

11. Why are these conditions accompanied by a great deal of pain?
With less serous fluid and swollen membranes the organs move with friction causing pain.

12. The mouth, or buccal cavity, and its extension, which stretches through the body inside the digestive system, is not listed as an internal body cavity. Why is this so? because there are openings to the outside environment at both ends of the cavity (mouth & anus)